Metastatic pheochromocytoma/paraganglioma in a child with von Hippel-Lindau disease: An uncommon cause of paediatric hypertension

Joshua Stanley MD[1], Jonathan D. Wasserman MD, PhD[1]

[1] Department of Pediatrics, Division of Endocrinology, The Hospital for Sick Children, Toronto, Ontario, Canada

Background

- Von Hippel-Lindau (VHL) disease is the most common inherited cause of pediatric pheochromocytoma/ paraganglioma (PPGLs)
- Tumours may be multifocal (either synchronous or metachronous), while metastatic PGGL are rare (estimated rate of 5-8% in VHL disease)

Case Presentation & History

- 6-year-old previously healthy boy
- Referred for bilateral cryptorchidism
- Abdominal-pelvic ultrasound: incidental retroperitoneal mass in the right supra-renal fossa, two additional retroperitoneal lesions
- No symptoms of catecholamine excess or family history of PPGL or endocrine neoplasms
- Asymptomatic hypertension (peak sBP 149 mmHg)
- ^{68}Ga-DOTATATE imaging confirmed avidity and identified subtle uptake at a 4th (midline abdominal) site

Biochemistry

Analyte	Ref Range	Pre-op Value	Post-op Value
Nor-metanephrine	<0.9 nmol/L	**>7.50**	0.53
Metanephrine	<0.5 nmol/L	0.37	0.12
3-methoxy-tyramine	<0.3 nmol/L	0.2	<0.11
Urine VMA	≤18.0 umol/L	**28.0**	N/A
Urine HVA	≤9.0 mmol/ mol Cr	4.8	N/A

Pre-operative Imaging

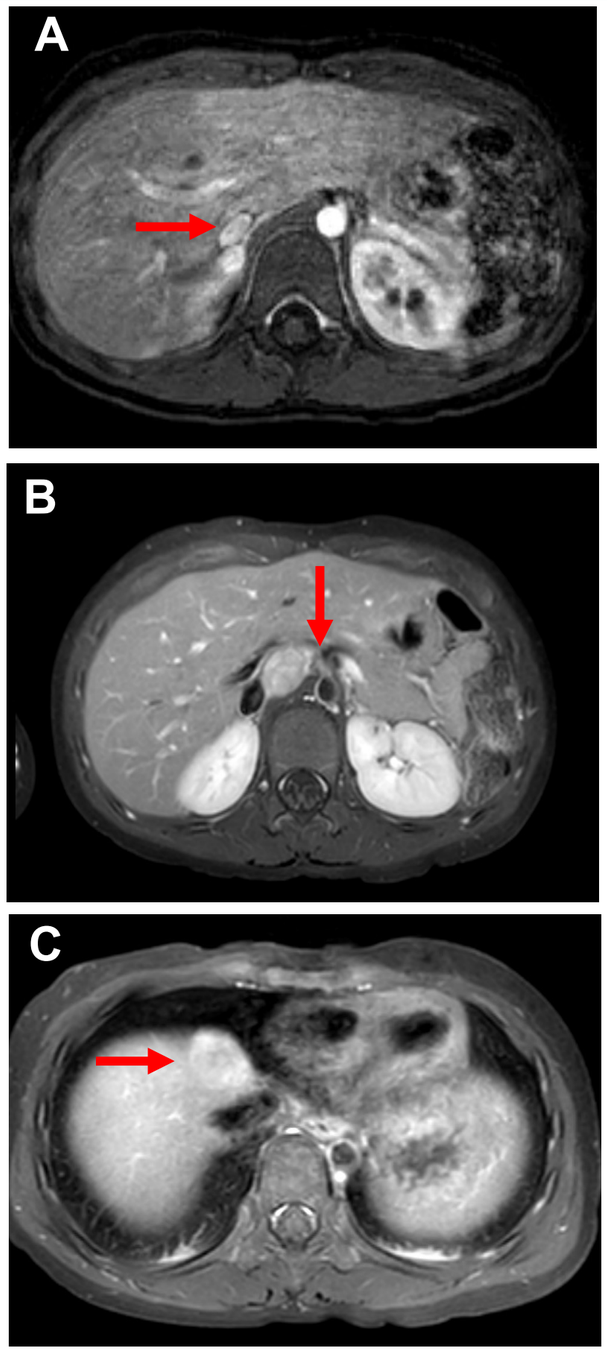

Fig 1. MRI abdomen of 3 heterogenous enhancing lesions (1.1-2.6 cm): (A) right adrenal gland; (B) mid-line retroperitoneum; (C) adjacent to right liver

Operative & Post-operative Status

- Uncomplicated right total adrenalectomy and excision of multiple paragangliomas
- Post-operatively:
  - Remains normotensive
  - Normal metanephrines
  - No residual disease on imaging

Intra-operative Findings

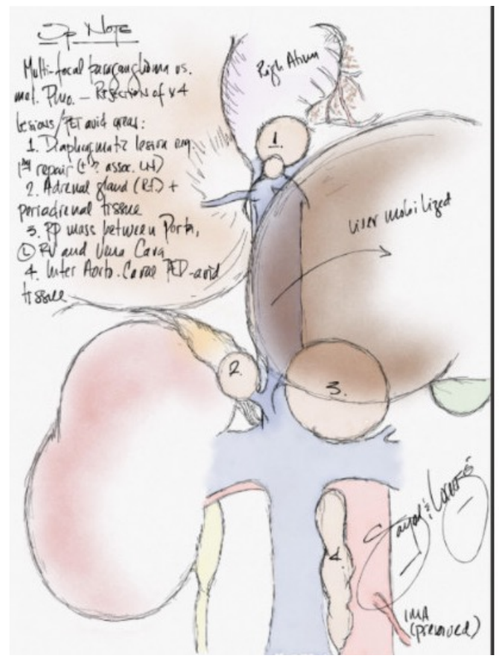

Fig 2. Intra-operative findings:

1) Metastatic sub-diaphragmatic PPGL (positive margins)

2) Multiple right intra-adrenal PGGL (negative margins)

3) right extra-adrenal PGGL (negative margins)

4) Infrarenal sympathetic chain (no PGGL)

Pathology and Genetic Testing

- Pathology of subdiaphragmatic lesion: ***metastatic disease*** instead of ***multifocal***
  - Rationale:
    - atypical tumour site
    - extensive infiltration of connective tissue and vascular space
    - lymph node containing tumour cells
- Germline analysis:
  - *de novo* c.482G>A variant in *VHL*
  - VUS c.415G>A in *FH* gene (disease modifying vs incidental?)

Key Messages

- Highlights the importance of histologic scrutiny with PPGLs located in atypical locations and of germline analysis for any child presenting with PPGL
- Germline analysis for all children with PPGL allows for pre-symptomatic surveillance to minimize morbidity attributable to associated lesions

TEMERTY FACULTY OF MEDICINE
UNIVERSITY OF TORONTO

SickKids